



## Bio-Reset and Complete Treatment of Chronic Glaucoma Center for General Informational Regenerative Medicine and Ophthalmology

**Massimo Lombardi\***

*Ophthalmologist - Regenerative Medicine Specialist, Lombardi-Eye-Clinic, Rome, Italy*

**\*Corresponding Author:** Massimo Lombardi, Ophthalmologist - Regenerative Medicine Specialist, Lombardi-Eye-Clinic, Rome, Italy.

**DOI:** 10.31080/ASOP.2022.06.0605

**Received:** November 30, 2022

**Published:** December 19, 2022

© All rights are reserved by **Massimo Lombardi**.

### Abstract

**Presentation:** It is necessary to “Re-Formulate” -in Toto- “the Clinical Perspective of Glaucoma” since it has been focused “mostly” on the “Control of intra-Ocular Pressure Rise” caused by a “Progressive Increasing Resistance to Water Mood’ Outflow” in “Schlemm’s Canal Trabeculate”.

A “Reductive and Myopic Vision of the Problem” which, in fact, has allowed “in the last centuries” “superficial and erroneous -Scientific- Thinking” unable to understand the “True Reasons” and not only the “Consequences” of the well known Clinical Phenomenon, that the Progressive Increase in Ocular Pressure inevitably leads to an inexorably worsening of visual functions as the: Visual Field, Visual Ability and Acuity, Color Vision, Contrast Sensitivity and Night Vision, up to a “Progressive Blindness”.

**Keywords:** Chronic Glaucoma; Collagen; Lamina Cribrosa

Schlemm’s channel, made by “Collagen”, where the “Aqueous Humor” flows, is the internal liquid of the eye whose “pressure balance” contributes to the maintenance of an internal constant volume with the “Normal Eye Pressure” (12-18 mm-hg).

“Lamina cribrosa” is the posterior “spongy reticular structure” of the Eye in continuation with the Sclera = that is the “Hard” tissue that contains the internal structures of the Eye, which are formed always by the “Collagen” that changes in “consistency, thickness and resistance” - “reacting more”, (where it is “softer and more reticular”), to a Chronic Inflammation, with this sequence: “Toxin-Irritation->Inflammation->Edemization->Thickening->Shrinking->Compacting-> Sclerotizing->Hardening”.

Meibomian and Zeiss glands are placed on the edge of the Eyelid and do “lubricate” the “Conjunctiva”, (Mucosa) inside which the Eye “rotates”, but, in “pathological conditions”, these glands

act as “vicariant draining lymphatic’organs” for “clogging” from “overload” of those normal “main physiological Emunctors” such as the Whole Intestine, the Urinary and the Sweat Systems. “Gratiolet’ Optical Radiation” are the nerve fiber bundles of the Optic Nerve that connect the “Retinal photoreceptors” that is the “visual” sensors (such as the pixels of LCD screens) with “the optical area” placed in the “occiput of the skull”, which is the “TV screen” where you can see the images taken by the “Camera” that is the Eye.

Calation: is an outgrowth, a “Bump” on the skin of the upper or lower lid, similar to the “Sty” but this last with a faster growth both are caused by the “Stomach-Intestine-Intoxication”. “Sclera” that is the semi-rigid and compact tissue, made of “Collagen”, which constitutes the envelope containing the various parts of the eye: crystalline, vitreous, uvea, iris and retina that comes out, opening like an overturned umbrella: “Optic Papilla” through the: “Optic Foramen”. “Nose-Lacrimal’ channel”, (made of “Collagen”),

which is the duct that “drains the tears” after lubricating the eye, located in the inner part of the eyelid opening near the nose and carries the “Tear fluid” through the nose -> into the esophagus -> into the stomach -> into the intestine and is through this “Forced-Circuit” due to the “anatomical organization” that “Pathological Intoxication” can create a “Vicious Circle” that cannot spontaneously “End” because it works in a “Circle”.

As in a “closed circuit” = “Loop”.

### Introduction

The Author has intuited the “True Cause” of Chronic Glaucoma, in the December 2020, having been “sick for 40 years” from 35 to 75, up to January 2021.

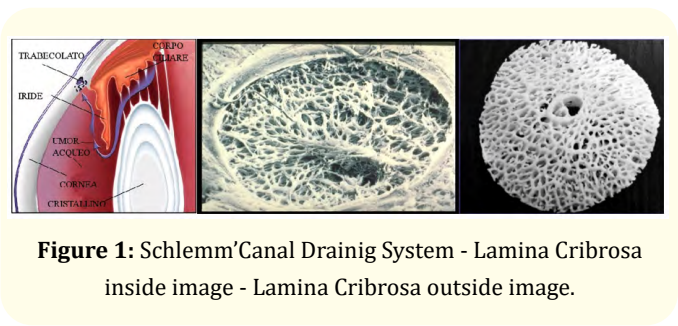
Chronic Glaucoma is mainly caused by a “Toxic Chronic Inflammation” of the “Stomach” and of the “Whole Intestine” including Organs as the Liver, Spleen, Pancreas, Gallbladder.

This “IS” the “True Initial Cause of Chronic Inflammation” - Secondary” to “Chronic Irritation” of the Eyeballs” due to “Toxic, PH-Acid Tears” that “continuously wet the eye” and that do “irritate” the ocular structures “inside the Eye”, provoking a “Secondary Inflammation” of the same.

Structures causing a secondary “Chronic-Cytokine’ Storm” and subsequent -> Edemization with Progressive Shrinkage of the Collagen Structure of the Drainage’ pathways of the Aqueous’ Mood that is the Trabeculate of the Schlemm’ Canal, giving rise to an “Initial Damage”, thus increasing the intra-ocular Pressure and subsequently, with a similar mechanism, but “internally and posteriorly” the “Lamina Cribrosa” on the Eye-Bulb, which is also made of “Collagen” that is the last and definitive seat of the “Functional Progressive Damage” involved in the “Chronic Toxic.

Inflammatory process” caused by the whole Intestiny’ Intoxication as well.

The “Cytokine Storm” is capable of causing a persistent Chronic Inflammation and Edemization for a “Definitive Damage” of the Optic Nerve, with a “Progressive Strangulation” of all Structures that pass through the “Lamina Cribrosa” as the: Central Artery and Vein, secondary arteriovenous vessels, lymphatics vessels and all the nerve fibers that terminate anteriorly in the Retina and



**Figure 1:** Schlemm’ Canal Draining System - Lamina Cribrosa inside image - Lamina Cribrosa outside image.

posteriorly in the anatomical structures that are called: “Gratiolet’ Optical Radiations” ranging from the Optic Nerve up to the “Visual Areas” into the “occipital brain” after having crossed the entire cerebral mass of the Skull from the Front to the posterior Occipital Brain.

We can define the “Chronic Glaucoma” as a “Collagenopathy” because of the continuous Toxic Irritation-Inflammation of the Collagen Structures of the Eye in particular the “Schlemm’ Channel” inside the Eye and the “Cribrous Lamina” in the posterior part of the Eye, through which pass the anatomical structures of the Optic Nerve that are all damaged by the “Secondary Edemization” caused by the Chronic Irritation with a progressive Shrinkage of all the Collagen Structures and by a final “Ischemia” by the Strangling of the Optic Nerve vessels and nervous fibers.

The Importance of PH: that is, the concentration of the degree of “Acidity” in the Blood that in the “Physiological’ Conditions” should be 7.5 - 8, just as it is at the “birth” of a “healthy baby” for the perfect functional efficiency of the “Kidneys” (see the principles of - Chinese Natural Medicine -). “Acid” values are already at 6.5, if lower it becomes “very acidic” as a consequence of the type of “Unnatural” and “Toxic Food and Beverages” which set in motion an “Attempt at Physiological Compensation” by mobilizing the “calcium carbonate” from the bones to “buffer” the “acidity” and allow the “kidneys” not to damage mostly the “Glomeruli”.

“Kidney is the Most Important Organ”, in Natural Chinese Medicine, and the most “Vital”, more than the Heart itself, which is the second most important and vital Organ.

The “Osteoporosis” will persist till the “Decompensation” of the: “Physiological State of Alkalinity” will continue, that is, outside and “Below” the values of: 7.5 - 8 of PH.

“Mechanism Action”: of the Pathology: “Chronic Inflammation of the Conjunctival Mucosa”: This “Chronic Inflammation” is the consequence of the release of toxins that go “Initially-Yes” through the “normal routes of expulsion”, the normal “Main Drainage’ Systems”, the feces, sweat and urine, but when the “toxins” are in “excessive quantities”, they find others routes or “vicariant systems” of “Drainage and expulsion” such as the “Lymphatic - Vicariant - routes”, up to Meibomian and Zeiss glands, present in conspicuous number, in the eyelids edge anteriorly on the Eye and posteriorly and internally up to the “lymphatic vessels” of the Optic Nerve which cross and supply precisely the “Lamina Cribrosa” and the inside anatomical structures. The Calation and the Sty are occluded Meibomian’ Glands that protrude in the skin of upper or lower lid because of the inflammation of the same caused by the Toxins Expulsion through the Meibomians Glands, not created for this function, on the Conjunctiva.

Calation has slower growth the Sty a very fast one, “acute”, evident and painful growth both are the expression of the anatomical-functional “vicariant” relation between Stomach-Intestine and the Meibomians and Zeiss Glands into the lids.

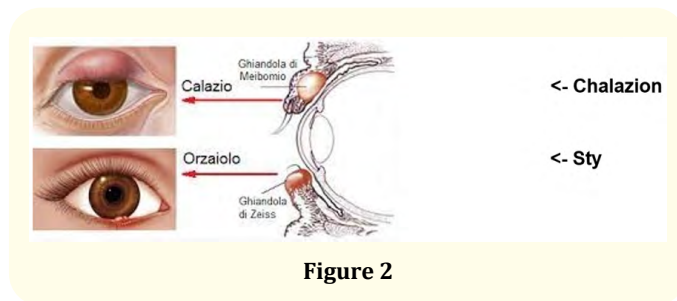


Figure 2

This continuous emission of Toxins, which are at Acid PH generates a: “Chronic Inflammation” and a “Chronic Cytokine Storm” secondary to the Inflammation, which has not been “foreseen” in “Cyborg’ Creation and Programming” = the “Human Being” (and mammals on Earth), and so there is “No - Solution” -> to a Chronic Damage mostly by “Artificial” chemistries (as Chemical-Synthetic) “if not” by starting and implementing those “Drastic-Changes” of Lifestyle and Nutrition “that-alone” can lead the Patient back into the “Correct Original Programming”, that is the only “possibility to endure many inflammations” - “Yes”, but that “- MUST - be resolved anyway” in a “Reasonably Short Time”, by a Repair program “already existing”, “But Not” for several “Chronic Inflammations

lasting-too-long” without a term -> = without a hope for a “Final Healing Solution”.

Prof. Recheweg (the Father of Homotoxicology), with his Geniality, places “Glaucoma” in his “Homotoxicosis’ Table” in the: “Cellular Phase” of “Degeneration” of the “Ectodermal Sensory Tissue” of the Eye.

It is certainly not with the use of “chemical-synthetic pharmacological anti-inflammatories” that cause severe “collateral toxic effects”, that we can resolve the “loop” that is the “vicious-circle” that is created in the Body following the “Intoxication -> Chronic Inflammation” and “Toxins’ expulsion” through the “Vicariant Lymphatic Emunctors” pathways, that are the “Meibomian and Zeiss glands” which ejects out of the “eyelid rim” the Toxins on the “Bulbar -Conjunctiva” which is a “Mucosa” of about “10 square cm of surface” x each Eye that cannot metabolize neither deactivate Toxins nor neutralize them from their “Toxic-Irritative-Inflammatory’ effect” therefore after they have carried out their “irritative action” with a sense of “sand, burning, irritation like from small stings and redness” that “are” poured out again with the tears that lubricate the Eye ending in the “Nose-Lacrimal-canal” and therefore in the Esophagus, Stomach and in the Intestine Nose-Lacrimal-Canal->.

Tears flow with the Toxins and back again on the Eye Conjunctiva in a continuous “Loop”.

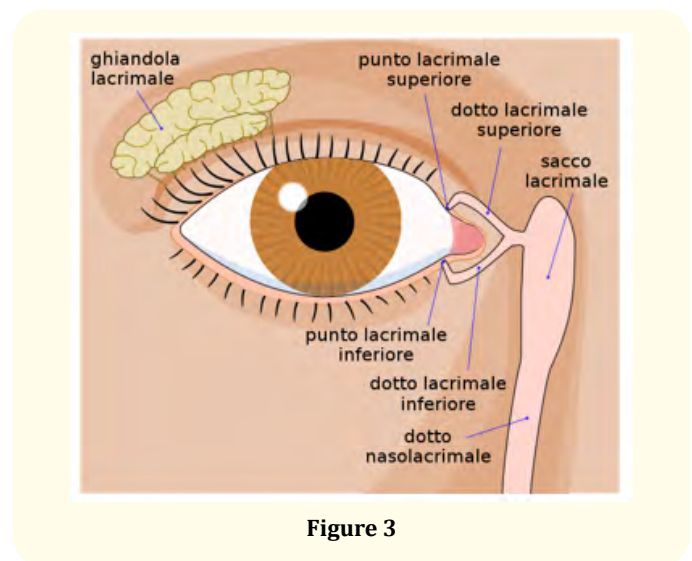


Figure 3

Reactivating and increasing the “Loop” or “Vicious-Circle” without a “solution of continuity” that can only “get worse”, with the Chronicization by Concentration from the “Accumulation”, of the toxins not expelled, which are re-introduced into the “Loop” increasing the general “Cytokine’ Storm” progressively worsening the Clinical Situation with “continuous increasing concentration” of “Gastro-Intestinal intoxication” by which Patient is “More or Less, but not Properly, Conscious” and therefore with the “Initial-Glaucoma”, which is only “one” of the “possible consequences” of “Chronic Intoxication” with “Reactive Shrinkage -> by Progressive Inflammatory-Edemization” “of the “Collagen Structures” of the Network of “Aqueous Humor of the Drainage’ Channel” that is the “Trabeculate of the Schlemm’ Canal” in the internal front part of the Eye and of the “Lamina Cribrosa”, located posteriorly in continuity with the Posterior-Sclera (of Collagen), but with a “different density and compactness”, similar to a “Sea sponge” perforated over its entire surface to allow the passage of: the Central Artery and Vein, Lymphatic vessels, Nerve Fibers and minor Artero-Venous vessels of the Optic Nerve giving rise to a Pathology defined as a: “Toxic-Chronic-Inflammatory-Collagenopathy” resulting in a “Chronic-Glaucoma- Worsening”.

It is as if the Eyes are “-frying- on a very, very low but continuous Inflammation” to the point that with the “Chronicization of the Phenomenon”, “Addiction” is created with a “False Reduction” of the “Clinic Evidence” of the “Symptoms” of the Inflammatory Process in progress and with an “Attenuation”, sometimes up almost to the “Disappearance”, of redness, burning, or sensation of sand or of a foreign body, or slight stings as caused by many needles and so on.

It is the “Body” that tries to “Compensate” the “Metabolic Imbalance” as to “Assimilate it to Integrate it” in a “Pseudo-Metabolic-Normality” almost “Normalizing and Hiding” the Initial “Symptomatology” of “Surface” as “Conjunctival Irritation” - “not only Unable but also Failing” to Compensate the “Chronic Damage” that will become worse, over time, “the rise of intra- Ocular Pressure” parallel to the “Progressive Narrowing of Schlemm’s Canal” anteriorly and of the “Lamina Cribrosa” posteriorly with those functional visual damages that are a Common Experience in this particular Illness.

Interestingly, with the “Healing Process” induced by my “Therapy” the Patient “Slowly, but Progressively” Not Only

“Regains” the “Lost Sensitivity” to the Increase of intra-Ocular Pressure for the “Reactivation of the Specific Sensory’ Terminals” but also at the same time the Patient Regains the “Sensory Capacity of the Conjunctival Sensitivity’ Terminals” to the “Irritation” -> “Inflammation” with Eyes that “Return to be Red” and feel “Burning Again” due to the “Regained Sensitivity” to the Toxins; “YES” it’s like if “Biologically the Patient could go back in the Time”, like in a “Moviolas”-“rewinding the movie” that is as the Patient could go back at the beginning of the “Lost and Forgotten Symptoms” as over described.

In reality it is just as Prof. Recheweg described us: you get “Sick and Progressively get Worse” by moving into the “Homotoxicosis’ Table” from “left to -> right”-“BUT” we can obtain the “Inversion” of “Direction” from “right -> to left”, “Only After” that we have Established for a “Reasonably Long Time” - a “Correct and Effective Therapy” including a “Deep Change to the Wrong Nutritional Habits” because this is the “only way” to go back, “in fact”/“back in the - Time -” and “reverse” “Clinical Situation” of the “Worsening” and subsequent “Chronicization” of the Pathology towards a “Clinical Improvement”, till up, -in the long time-, to the “Definitive Resolution of the Glaucoma”.

The complexity of the Mechanism of Action of “Intoxication -> Inflammation -> Coarctation” of “Collagen” also resides in the “necessary comparison” of the notable “inequality” between the “surfaces” involved in this pathology ; from a side the sum, (in square centimeters), of the Endo-Gastric and Intestinal Surfaces, (Choledochus, Gallbladder, Pancreas and Liver’ducts) while on the other part the “decidedly lower sum of the Surfaces of the Conjunctives” of the two Eyes that is calculated in about 20 square cm x both Eyes”, - thus managing - to understand the excessive “Disproportion” of the “relative quantity” of “Surfaces involved in the Pathogenetic’ Mechanism” from the Collection of Toxins first produced and released by the “extensive intestinal mucosa” and then “expelled” through the “vicariant lymphatic pathways”, on the “reduced Conjunctival-Mucosa surfaces of the Eyes” and it is - so easy to understand - the “Extreme Concentration” of the quantity of Toxins that can affect the “second” ones that are the Eyes’.

Conjunctiva (a Mucosa) caused by the “Systemic-Intoxication-Inflammation” and that, “if the Patient reacts “in time”, with “serious and radical dietetic’ measures” to “stop and contain as

much as possible the Chronic Intoxication” -since it does not exist any other possible way of exit- from this “Silent but devastating Pathology” with its “Progressive Damage”, also if with an intra-Ocular Pressure “Correctly-Hypothesized” after a “Lucky and Successful-Surgical-Intervention” that maintains the intra-Ocular Pressure “Stably-Low” (day and night) at 12/14 mm of Hg. “But” with a “Progressive-Damage - not - Interrupted” - of the - visual fields, sight and loss of colors- as it also happens in “Low Pressure Glaucoma” which is explained in “Only-One-Way” possible, that is with the “Edemization -> Strangulation -> by Coarctation and -> Progressive Ischemization” which, even if the intra-Ocular Hypertension (with the intervention) has been “resolved”, which represents only the “First Problem” the “most obvious”, but not the “Second Problem”, the “More Subtle One” because it is less “Evidently Verifiable” and it is “Harder to be Resolved”: the “Progressive Shrinkage” of Posterior “Lamina Cribrosa” by the “Inflammatory Collagenopathy” which is “Retro-Bulbar” where pass: the “ Main Artery and Vein” afferent to the Optic Nerve and the Optic Nerve’ fibers and the Choroidal Artero-Venous vessels, the afferent and efferent Lymphatic Vessels these are Responsible for “Toxins” transported into Lamina Cribrosa. Therefore these “Fundamental Structures” are “Inexorably Strangled and Ischemized” by the Inflammation thus explaining the “Progressive Trend” of the “Damage of the Fundamental Visual Functions” up to “Blindness” even if there is a “Hypotonic Pressure” that is “lower than normal” as in “Low Pressure Glaucoma” and “post-operative Glaucoma” with acquired “pressure control”.

Also in “Natural Chinese Medicine” the “Life-Energy” connection of the Energy Channel: “Zu-Yang-Ming” which starts from the lower part of the Eye and ends in the “Melluce Finger” (second toe from the Big Toe) “passing through Stomach and Intestine”, demonstrating the clear “Energetic Connection” as well as “Anatomical” which explains the “Co-Interest” of the two Main Organs involved in the pathology: “the Eye” and the “Stomach” (including the Intestine) the first: is a “Full-One” -> “the Eye” that is “Twinned”- (in Natural Chinese Medicine) - with an “Empty-One” -> the “Stomach”.

The “Energy Imbalance” of the Energy Channel of the “Eye -> Stomach” “Zu Wang” is for the “Chinese Natural Medicine” the explanation of the “Gastro (Stomach)-Glaucomatous Disease”.

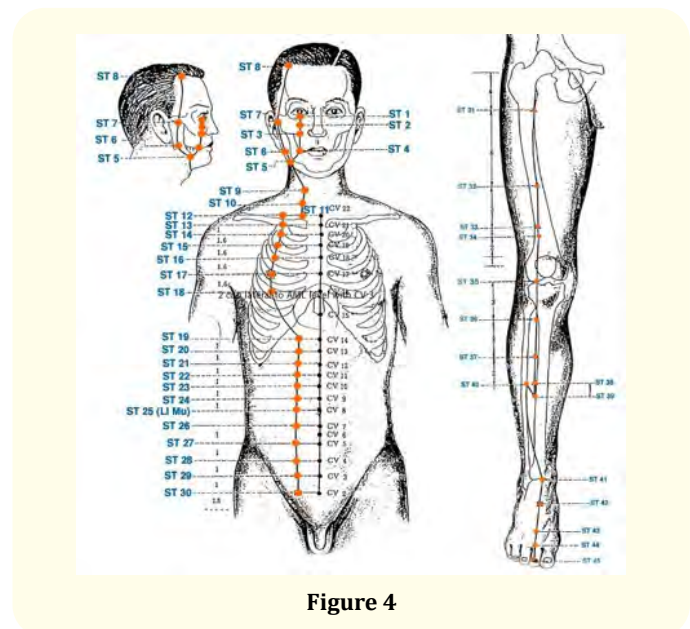


Figure 4

We should also consider the Conjunctiva, (which is a Mucosa), as a very “Sensitive-and-Fine-Thermometer” and “establish” that the “-TRUE-” state of “Health and Well-being” of the Human Body can be determined “mainly” by an “-ABSENCE-” of “Toxins in Excess” that therefore are “correctly metabolized and neutralized” by the “Normal-Excretors = Emuntors-Organs” when without “Excess” are “Disposed” through “other ways” such as: the “Conjunctival Mucosa” and the “Lamina Cribrosa” that have been forced to become “Unnatural-Vicariant-Emuntors-Organs”.

The Beginning of the “Toxin’ Expulsion” over the Conjunctivae is a “Clear Index” of the “Metabolic Equilibrium’ Breakdown” that it is also the “First Symptom” of the “Intoxication’ Disease” preparatory to “Initial Chronic Glaucoma” and “Capable of Triggering” a “Chronic Cytokine’ Storm” not “Foreseen” by our “Creator” and therefore not included in the already existing “Biological Programs” of Mammals on Earth.

It is also necessary to “modify and update” the “diagnostic means and methods” and the “Criteria” for a “Correct and Updated” Diagnosis of “Initial Glaucoma”, in fact, until now, it was recognized in the “pejorative changes of the Visual Field”, the “Main Symptom” for the Clinical Orientation with which to first “diagnose” a “Beginning” and then with the “Worsening” of the “Visual-Fields” and “Visual Capabilities” the “Clinical Worsening” of the Disease.

But with a careful observation, “today”, it is possible with “the advent of Retinal OCTs” to verify the “Anatomical-worsening” as the “True Beginning” of the Pathology with “the initial Progressive Excavation and Depression” as a “Cup’ Bottom” towards a “Cone Shape” of the “Optic Papilla”- “long before” that the “functional deterioration” can occur to the Visual Field, moreover.

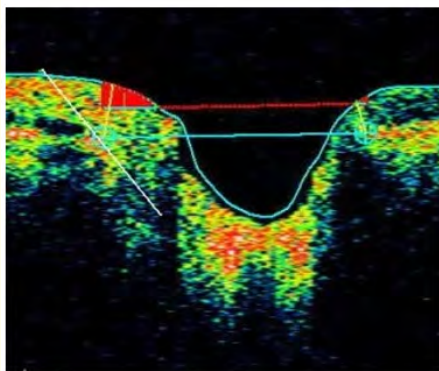
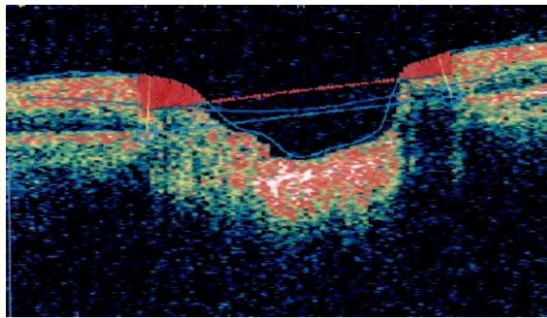


Figure 5

“Often, it is waited too long” to make a Diagnosis of “Initial Glaucoma” and therefore to be able to prescribe a suitable hypotonic therapy, erroneously based, “Solely” on the “Higher” intra-ocular pressure than the one considered normal of 12-18 mm of Hg.

Also the different instruments used to measure the intra-ocular pressure that we do not know how correctly calibrated they are, and the different operators not necessarily “correctly” trained to a “precise measurement”, correctly repeated to compare the measurements.

In fact, “correct measurements” should be compared, in the time, at least by the: “Same operator with the same correctly calibrated instrument”.

We cannot rely, “today”, on a “Diagnosis of Exclusion of an Initial Glaucoma” if “not” a “higher pressure is found” at the visit of the Specialist, since, “the Oscillation” of the Pressure’ Increase is thus “Variably Fluctuating” in the “early years” to cause, with the “Progressive Sclerotization” of the “intra-Ocular Draining Structures” such an increase in the “ocular-Pressure” to be found by the Specialist, in “Parallel Response” to the increase in the state of “Reactive-Inflammatory Sclerosis” of the “Collagen’ Trabeculate” first and after of the “Lamina Cribrosa”, before the disease causes its “First Anatomical Damage” such as the initial displacement of the “Main-Vessels” towards the nose in the Retina called “Vascular-Nasalization” and subsequent “Kneeling” at 90 degrees against the “rigid scleral border-edge” of the “Optic Foramen”, made by “Hard Collagen” with a further “Ischemizing Effect” of the Retinal Vessels and Nerve Fibers that enter into the Eye like an “Overturned Umbrella” => the Retina.

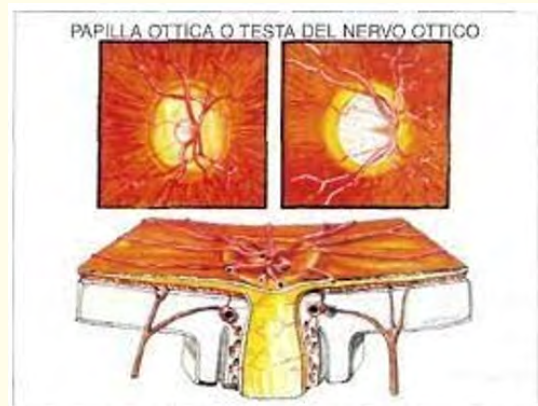
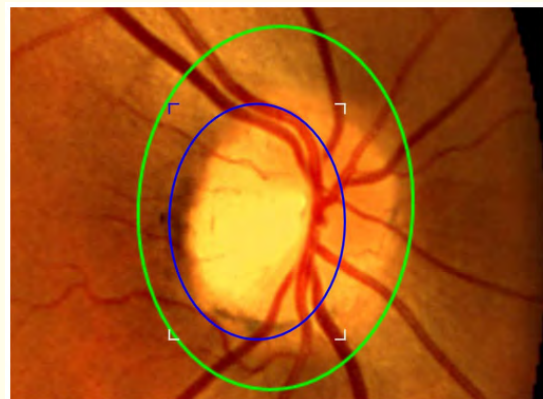
Figure 6

With the initial “crushing” as a “cup’ bottom” of the “soft unmyelinated fibers” of the Optic Nerve and a subsequent, slow but continuous and progressive excavation for Progressive Compression “from cup’ bottom -> to funnel” of the “Optic Papilla” and in the more advanced phases also the Nerve un-myelinated fibers of the O.N. undergo for “Crushing”, (due to the increase of intra- Ocular Pressure), to a “progressive thinning of the thickness” (in microns) of the “nerve fibers” and also this objective datum and its progress can be easily found with the OCT programs.

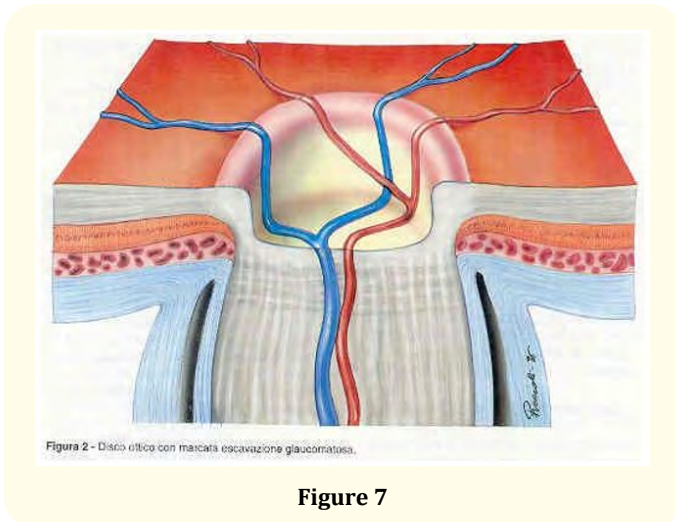


Figure 7

So only an “early, careful and accurate examination” of the OCT that examines the Papilla, with a “Precise examination of the initial excavation” and if “already present” also of the “initial thinning (even if minimal) of the nerve fibers ”should alert” an “Attentive” Ophthalmologist long before “Symptoms” as “visual field and visual deficits” can be identified and the disturbances reported by the Patient being ascribed precisely to an early Glaucoma.

An “Accurate Anamnesis”, in the “Light of my Discovery”, involves “new kind of questions” to be posed to the patient, based on the Clinical Evidence of the First Symptoms of this progressive “Intoxication -> Inflammation” of the Conjunctivae.

We must ask to the patient: how do you wake up in the morning ? If with a “blurred” vision that is lightened only by repeated rinsing of the Eyes with running water whose “meaning” is the “Presence” of an “Altered-Toxic-Secretion” from the “Meibomian and Zeiss Glands”, this “Clinical Symptom” which is “Regularly-

Underestimated” by the Patient represents “in reality” the “First Symptom” in the “Evidence Based Medicine” of the Pathology “already” in “Clinical Evolution” and when the Eyes are “Red” upon awakening, this is the Specific “Second Symptom” of the “Toxic-Irritative-Process” in Progress and when the Patient has also during the day “Red and Inflamed Eyes” with the well-known sequela of the Accessory Symptoms as the sensation of Burning, Sand, Foreign bodies and Lacrimation defects, sometimes even with Hypo-Lacrimation other “Secondary Symptom” to “Chronic Conjunctival Toxic-Irritation” which can easily lead to “functional defects” also of the “Lacrimal Gland” with Lacrimal Hypo-secretion, and also a “Narrowing” of the “Nose-Lacrimal-Canal” (always in Collagen) that represents also another Symptom of “Reactive Shrinkage to the Chronic-Inflammation” due to the “irritative transit” of the “Toxic-tears” into the “nose-canal”, this Symptom “can also recede” once a “good degree” of “Biological-Control and re-normalization of the Normal-Emunctorial-Drainage” has been reached and when “washing Eyes with running water” becomes “much more effective” mostly by using: “Alkaline-Water” instead.

We have to reprogram our style of life for Food and Beverages and change Awareness about How Badly we treat our Stomach and Intestine, we need “correct updated informations” about “what” is “Really Healthy, Good for Food and Beverages” for our “Stomach and Intestine”, - to day -, we must have the greatest respect for these two Organs, “like a Temple”, from whom depends our “Wellbeing, Health and Longevity”, we “Eat and Drink Consciously or not Rubbish and Poisons” not thinking to “Suffer Bad Consequences from our Wrong Conscious or Unconscious Behavior”.

We cannot trust Industries of Food and Beverages Products thinking Ingeniously and Stupidly that they work for “Our Health” and not only for their “Economical Income”, as the many “Agriculture Products” full of Poisons and GMO that will enter irreversibly in our Organs, Tissues and Cells.

Let’s introduce now the Therapy that I have “discovered and studied”: - with a more correct Therapeutic approach, that is necessarily - “Holistic” - First is necessary to eliminate - the “sources of Progressive Food and Beverages Poisoning” and also from the “Use” and “Abuse” of “Toxic-Chemical-Synthetic-Therapeutic-Drugs”.

This topic is “too long and complex” to be addressed here and in necessity of a “long series of information” that -Would Overturn- “Erroneously Rooted Beliefs” believed to be “Healthy Eating Habits”, in a “world, now, completely Changed and Poisoned by the Industrialization” of the “Production-Chain of the Vegetables, Fruits and Animals’ Food” such as “GMO” and also from “Chem-trails, Herbicides, Preservatives and Glyphosate” that represent only a “partial example” of the “Panorama of Poisons” of our “Present Deteriorated World”.

There is also a “Systematic Poisoning” of many drugs of which a part is for consequence of the Pharmacological Action of the type of product but other “Poisons” are added “Deliberately” with Purposes that if you are “not too Stupid or Superficial” it is easy to understand “Documenting” Yourself about the “Depopulation Program and Agenda” on the web.

Here is the procedure to follow for my Therapy: First-Phase with the “Reprogramming of a more Correct Diet”, having provided the Patient with all the Necessary Informations to “Reduce as Much as Possible” the Introduction in the Stomach of further “Toxic Substances” with the Food and Beverages and Poison Chemistries in the Body.

Obviously at First Doctors should up-grade their Knowledge to understand the Toxicology of all Products that Patient could introduce in his Body and Restore an Healthy Diet and Therapy.

Second-Phase, to “Detoxify” from “previously-Introduced-toxins” by treating the Patient with: An “Ionic Removal” of the “Accumulated Toxins” in the “Adipose” (Fat) tissues over time and also in the “Intercellular Spaces” and in the “more advanced phases” - “into the Cells”, our organism being an “Osmotic Membrane” which “unfortunately” holds an “Excessive-Toxin-Load” for a “Normal Emuntorial Function” and therefore the “Toxins” are for the most part withheld inside the “Osmotic Membrane that is our Body”, especially into the “Fatty Tissues”.

With an “Ionizing Apparatus” capable of immersing the feet in a basin of hot water with a pinch of salt to allow the “Ions” pass through the Skin and an electrode in the center of the basin and a bracelet around the Wrist with the other electrode for establishing a “flow of Ions” that expel through an “Inverse Osmosis” from the

Skin of the feet and ankles immersed in water, Toxins, Catabolites and Heavy Metals, all Substances whose abundant “Intoxication” represents a premature Tissues Damage => Pathologies and consequently a Faster Aging.

Trade name of models, that you can find, at very reasonable prices, on the web, is: “Foot-Spa”. The treatment must be done with the “precautions related to the state of health more or less compromised” and the age, interspersing a “Detoxifying Treatment” every 2/4 or more days by “evaluating” the time interval with the Doctor, case by case.

I am personally against the use of Detoxification as Drips’ infusion with EDTA and Anti-Chemical-synthetic inflammatories because in any case they are “Toxic” in turn.

“You also need to know” that we found in the “physiological solution”, which is used for the “drip” and also for the preparation of Pharmaceuticals, Homotoxicological, Organotherapeutic and Homeopathic drugs, traces of “Graphene Oxide” whose presence has been revealed by “Bioresonance” Devices.

The “Toxicity of Graphene Oxide “ is well known and present in the Scientific International Literature ; I proved that the “Ionization-Detoxifier” can also be useful to eliminate, over time, the “Graphene Oxide” can be also “deleted” by the Bio-resonance “Counter-Frequency” Apparatus.

“Homotoxicological Detoxification” to “re-activate” and “increase” the “Emuntorial-Detoxifying- Drainage” and also to carry out a more effective “Dis-Inflammation” of the Organism with the use of Natural Medicines as: “Arnica-Galium-Lymphomiosot-Lycopodium-Echinacea”, and others that “can modulate” a specific “ Anti-Cytokine” action, “Diluted and biologically activated” with “Succussion” = SKA (Sequential Kinetic Activation) up to its possible, even if not easy and fast “Termination”, which can occur in “a few and very determined patients ”, which I was fortunately capable to meet.

#The Author could recover himself from Chronic Glaucoma having the Privilege to verify the “Concrete Feasibility and Effectiveness” of the above and below Therapy.#

The Therapy is administered by mouth, depending on the severity of the Clinical Condition, 1/2/3 times a day with 3



(horizontal) fingers of "Informed Water" in a glass, for months, and some times years, evaluating the "Individual Clinical Situation" with your Homotoxicologist Doctor.

It is also needed an "Injective-Sub-Retro-Bulbar" Treatment of a "Galenic Solution" composed in part from the above Blend, "mixed" with other Organo Therapeutic Solutions, to be "modulated case by case" depending on the "Staging of the Main Pathology" and other related Diseases present in the Clinical History of that Patient.

The stings will be modulated, depending on the logistical conditions and the severity of the disease, in Cycles of 5-7-10-15-20-30 or more days possibly repeating the cycle 1 or more months later, the treatment can also be carried out once a week for at least 40 times that is 10 months and sometimes many more.

## Final Conclusions

This Treatment is the only one capable of reaching the posterior "Lamina Cribrosa" (also made of Collagen), involved in its initial "Coarctation" by "Reactive -> Edemization -> Shrinking" of the Collagen Structures involved in the Drainage' System" caused by a "Cytokine Storm" (as already above explained) started by a "Chronic Inflammation", due to Toxins expelled inside the organism which subsequently produces a state of: "Ischemia by Progressive-Strangulation" caused by the "Chronicization of Intoxication" which induces in the long time a "Reactive-Sclerosis" with the "Shrinkage" of the "Spongy" structure of the "Lamina Cribrosa" itself with the "Anatomical-Functional" structures of the Optic Nerve that pass through it.

The stings activate and promote both a "Remodeling" of the "state of inflammation" of the posterior part of the eye obtaining a "Detoxification-Anti-Inflammation" and Reduction of the Edemization' Shrinkage of the "Lamina Cribrosa" Spongy-Reticular Collagen fibers of O.N. "as first" and simultaneously activating an "Informational-Regeneration" of "Retinal and Optic Nerve Stem Cells" with the "Parallel-Progressive-Improvement" for the "Induced Cellular Regeneration" of all the "Visual Functions": from the Visual Field to the Vision of Colors and Acuity, all measurable and verifiable with specific tests.

Finally, a simple washing of the "open" eyes with "cold running water" if necessary "Assisted" by a "small plastic container", which can be purchased in the Pharmacy so you can "better" wash the Eyes,

that is a "Simple-Natural-Action" but "Extremely Effective" with the "Interruption" of the "Vicious Circle" and the "Removal of Toxins" from the Conjunctival Mucosa Surface that is already an "Efficient" - "Medical Treatment" - since the - "Washed-out and Removed Toxins" - "Will no Longer Re-enter" into "Loop" so that this Gesture repeated many times daily Certainly Represent an "Important-Therapeutical-Action" for the control and "Containment of the Toxins' Volume" involved in "Ocular-Intoxication-Inflammation-Edemization-Strangulation", in its Simple Execution. "Cold Running Water" has another "very important effect" because it reduces the "Inflammation" that causes an Increase of the Eye Superficial and Internal Temperature" provoked by the same, mostly by night, when sleeping, the "Increased Temperature" Increases the Eye-Pressure that will provoke more Damages of the Optical Nerve' Anatomical-Structures.

I have personally experienced this "Temperature' Increase" by washing the Eye' Conjunctiva and Cornea at night and sometimes at day with "Eye-Drops" made by Informed Water that flows in "drops one after the other on the Eye surface" - "looking up and tilting the face on the right side" to wash the Right Eye and the opposite for the Left-One, you can "slightly feel hot drops" running on the skin at side of your face.

With a source of pure, "controlled Alkaline pH 7.5-8" water the "Buffering" of the "acid PH" present in the "Toxic Tears" will be strengthened with a removal not only by "mechanical- washing", but also by "chemical-buffering-neutralizing" Toxins, with a "Feed-back" effect on the Stomach' Mucosa for the "Buffering Efficacy" of Alkaline Water, even if minimal but repeated several times in the day and night, in the Stomach, that it is already at Acid pH.

An excellent tool used by me for an "Effective Dis-Intoxication" is the "Ionizing Reverse Osmosis" commercial-device "Chanson" with a Japanese patent called "Kangen" that works with "Ionizing-Ceramic-Plates" which supplies Pure and Alkaline Water with "controlled 7.5-8 or more PH" supplying water with Active "Ions" and therefore more "Capable of Neutralizing the Toxins".

Any other similar, but effective device could be used for same purposes.

In Conclusion, we are facing a "complex therapy", but also, up to now the "Only Real Effective, verifiable and repeatable Solution"

for “Chronic Glaucoma”, capable of changing the fact that “once again” in the history of medicine, a disease classified as “Incurable” in fact, is transformed into a “Curable-One” and with a “Continuous Therapeutic Healing Commitment” will be possible live a more “Normal-Visual-Life” and even to a “Definitive Healing” in selected cases.

A last very Important Communication is that the above clearly explained Etiopathogenesis and Therapy can also be applicable to most of the Organs or Systems’ Diseases caused by a “Toxic-Chronic-Inflammation” that are about the 80% of all Chronic Diseases. The different types of Diseases can change from Patient to Patient and a Patient can be affected by more than one Disease.

Diseases can be group-able in one or more specific known typologies depending on variable factors such as Genetic Predisposition or Environmental Conditions and/or Type of Work as well as a Particularly Selected Diet for the type of Food and Life’ Style and also for the consequences of Specific Geopatic-Environmental effects on the human body.

Specific Diseases are therefore determined by one or more of these factors.

## Bibliography

1. Massimo Lombardi. “Retinal Stem Cells Reprogramming”. *Journal of Ophthalmology and Clinical Research* (2018).
2. Massimo Lombardi. “Retinal Stem Cells Reprogramming Using Homotoxicological Pharmaceuticals Blend Therapy through Retrobulbar Injections”. *Journal of Stem Cells Research* (2018).
3. Massimo Lombardi. “Retinal and Body’ Stem Cells Reprogramming”. *Acta Scientific Ophthalmology* 4.6 (2021).
4. Massimo Lombardi. “Biological Reset and Chronic Glaucoma Healing”. *Acta Scientific Ophthalmology* 4.12 (2021).