

*** Biological Reset and Chronic Glaucoma Healing ***

LombardiEyeClinic

**“Center for Regenerative Informational Medicine”
Rome**

Dr.Massimo Lombardi

Abstract:

The Author reports in this Article, how, after being affected by Chronic Glaucoma for 40 years, he could finally, through the consistency of the “Evidence Based Medicine” find a local and general Cure “Effective, often Decisive” against it, with Omotoxicological-Organotherapeutic Chemistries.

Summary:

The Author reports with this Article how, after having suffered a Chronic Glaucoma Disease himself (for 40 years), he found an Effective and “often” Resolving Cure with Local and General Therapy against Chronic Glaucoma with Homotoxicological and Organotherapeutic Drugs.

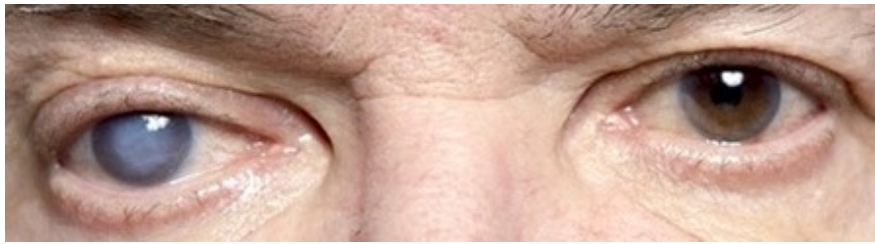Epidemiology:

A rough estimate is that Glaucoma affects about 80,000,000 patients worldwide by calculating the number of patients followed by the various (and not all connected) "Anti-Glaucoma Centers" In my opinion, this value indicated by the O.M.S. only the "Tip of the Iceberg" and does not take into account Asia and Africa where only a few centers are connected with O.M.S. and furthermore in the Westernized World it is likely that there are patients not followed by the Centers but by hospital' borrowed Eye' Doctors and / or private Eye Doctors without counting "all those who suffer from it" but have not yet reached a "specific diagnosis" these considerations lead to an “only assumed Estimate” for a total of 600,000,000 patients and for many researchers also this Estimate appears largely approximate.

Keywords:

Chronic Glaucoma: Disease characterized by an increase in Endo-Ocular Pressure that goes beyond the normal value of: 18/22 mm hg = (mercury) up to extreme values of 60/80 mm hg.

1) **RIGHT EYE: HIGH CHRONIC GLAUCOMA (SEVERE) WITH ENDO-OCULAR PRESSURE ABOVE 40/60 mm hg WITH CORNEAL OPACITY FOR SECONDARY EDEMA**

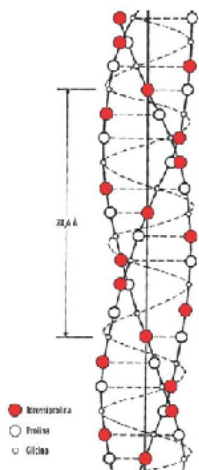


2) **LEFT EYE: CHRONIC GLAUCOMA WITH MEDIUM-HIGH PRESSURE WITH TRANSPARENT CORNEA**

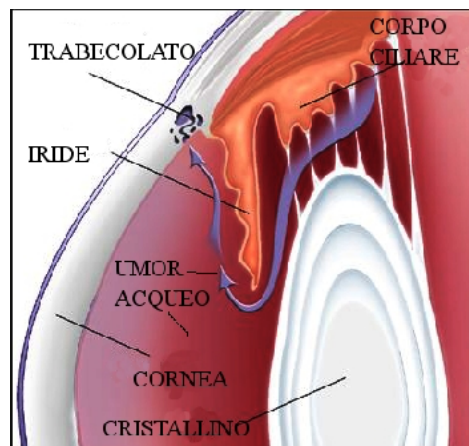
Collagen: body tissue, identical in basic structure throughout the body, present in ligaments, tendons, cartilage, synovium, Cornea, Sclera etc.

-The Collagen Diseases are called: "Collagenopathies", can affect the whole body as in the "Lupus Eritematosus" or only one tissue as in "Keratoconus" =>the "Cornea" with an "Infectious Collagenopathy" caused by "Aspergillosis" which, I was able to Discover and Solve in 1986.-

1) **COLLAGEN STRUCTURE**

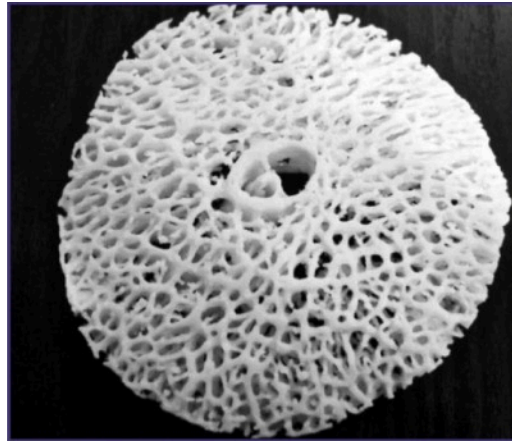


2) **WATER HUMOR LEAKAGE THROUGH THE TRABECULATE WHERE ENDO-OCULAR PRESSURE IS REGULATED**



Scleral Trabeculae: inside the circular channel called "Schlemm" that surrounds the base of the Cornea, in the inner part, on the periphery of the Cornea itself, made up of a Collagen network that serves as a "drain" of the "aqueous humor", produced by "Secretion" of the Ciliary Body, (a mixed structure), with the vascular part which borders on one side with the Iris (which gives color to the eye) and on the other with the spongy tissue, (a mixed structure), called "Uvea".

Lamina Cribrosa: (Cribrous-Foil) a structure made of Collagen which, like a network, allows the “myelinated nerve fibers” of the Optic Nerve, the Blood and Lymphatic Vessels to pass through the empty spaces of the “net” in continuity with the Scleral texture precisely called “Sclera or Sclerotic” due to its compactness and biomechanical resistance that covers the whole Eye.



3) RETRO-OCULAR CRIBROUS FOIL = LAMINA CRIBROSA

Visual Field: instrumental examination aimed at determining a primary visual function which, while one Person stares at the center with both eyes, makes see, at a "glance", even peripherally.

Sight: ability to read the "Optometric" table with letters / numbers to measure how many lines, or rather "Tenths" we can read at a distance of 3, or, 5 meters, from: 1/10 to 10/10, with each eye .

Myelinated fibers of the optic nerve: are normal neuronal fibers covered, once outside the eye, by "a sheath of myelin" (like an insulating envelope) to cross the brain.

Tachyphylaxis: phenomenon of “addiction to allopathic drugs” that lose their effectiveness even if with significant increase in the number of administrations, because Patients become use to them.

Keratoconus: “infectious collagenopathy secondary to Aspergillois’ Infection”.

Personal Clinical History:

I have suffered from Chronic Glaucoma since the age of 35 and I have tried all the therapies also with repeated sessions of "Argon-Laser iris’ plastic" and with "Jag-Laser micro-punctures of

Schlemm's canal", and the usual medical therapies with eye drops: Pilocarpine, Timolol etc. and during my recent cataract surgery and IOL implantation with antiglaucomatous surgical sclerectomies in both eyes.

Having consequently reported severe worse changes in the O.C.T. of the left Eye and partial damage on the right Optic Nerve, seeing that, by now, after 40 years (I am writing at 75) the situation was worsening faster, having also encountered the phenomenon of "Tachyphylaxis" with the antiglaucomatous eye drops, seeing an absolutely uncertain future for my eyesight.

I turned to the Most High, with a frank and net heart, and asked him for help.

The help came a moment later, when "suddenly" I doubted that this so serious Disease was not given to me as "a cross to bear to the end", but rather as a "profound stimulus" , which "involved me personally", to make me find a "necessary Solution" , as it is already happened with other diseases, discoveries and inventions that I had, previously, made with His Help, throughout my life since I was a 9 years old child.

(I-have been presented as the “youngest inventor in Italy and Europe” in a specialized Italian National TV Program for Inventors, 1955)

"Updated definition” of the- etiopathogenesis of Chronic Glaucoma-:

Disease caused by a "high degree of chronic systemic inflammation" with "chronic accumulation of toxins" with consequence that these last lead to a "high activation of inflammatory cytokines".

Located on the right side of the "Tissue Degeneration" of the “Neuro - Sensory - Ectoderm” in the

“Recheweg Complete Table of Homotoxicosis”.

OMOTOSSICOLOGIA
VERSIONE AGGIORNATA DELLA TAVOLA DELLE 6 FASI
“Le 300 diagnosi più frequenti”

SISTEMI ORGANICI	FASI DELLA SOSTANZA FONDAMENTALE (MATRICE)			FASI CELLULARI		
	Fase di Escrezione	Fase di Infiammazione (o di Reazione)	Fase di Deposito	Fase di Impregnazione	Fase di Degenerazione	Fase di Dedifferenziazione (o Neoplastica)
SISTEMA ENDOCRINO 1 - TIROIDE 2 - IPOTALAMO E IPISIFISI 3 - SOCRUTE	1 - TIROIDE	2 - TIROIDE	3 - TIROIDE	1 - TIROIDE	2 - TIROIDE	3 - TIROIDE
	1 - IPOTALAMO E IPISIFISI	2 - IPOTALAMO E IPISIFISI	3 - IPOTALAMO E IPISIFISI	1 - IPOTALAMO E IPISIFISI	2 - IPOTALAMO E IPISIFISI	3 - IPOTALAMO E IPISIFISI
	1 - SOCRUTE	2 - SOCRUTE	3 - SOCRUTE	1 - SOCRUTE	2 - SOCRUTE	3 - SOCRUTE
SISTEMA NERVOSO CENTRALE E PERIFERICO 1 - CERVELLO	1 - CERVELLO	2 - CERVELLO	3 - CERVELLO	1 - CERVELLO	2 - CERVELLO	3 - CERVELLO
	1 - CERVELLO	2 - CERVELLO	3 - CERVELLO	1 - CERVELLO	2 - CERVELLO	3 - CERVELLO
	1 - CERVELLO	2 - CERVELLO	3 - CERVELLO	1 - CERVELLO	2 - CERVELLO	3 - CERVELLO
SISTEMA MUSCOLARE 1 - MUSCOLI	1 - MUSCOLI	2 - MUSCOLI	3 - MUSCOLI	1 - MUSCOLI	2 - MUSCOLI	3 - MUSCOLI
	1 - MUSCOLI	2 - MUSCOLI	3 - MUSCOLI	1 - MUSCOLI	2 - MUSCOLI	3 - MUSCOLI
	1 - MUSCOLI	2 - MUSCOLI	3 - MUSCOLI	1 - MUSCOLI	2 - MUSCOLI	3 - MUSCOLI
SISTEMA OSTEOARTICOLARE 1 - OSTEOARTICOLI 2 - OSTEOARTICOLI 3 - OSTEOARTICOLI	1 - OSTEOARTICOLI	2 - OSTEOARTICOLI	3 - OSTEOARTICOLI	1 - OSTEOARTICOLI	2 - OSTEOARTICOLI	3 - OSTEOARTICOLI
	1 - OSTEOARTICOLI	2 - OSTEOARTICOLI	3 - OSTEOARTICOLI	1 - OSTEOARTICOLI	2 - OSTEOARTICOLI	3 - OSTEOARTICOLI
	1 - OSTEOARTICOLI	2 - OSTEOARTICOLI	3 - OSTEOARTICOLI	1 - OSTEOARTICOLI	2 - OSTEOARTICOLI	3 - OSTEOARTICOLI

sindrome di Sjögren, cataratta, retinite pigmentosa, glaucoma, distacco retinico, degenerazione maculare

Action' Mechanism:

The toxins generate a "Chronic Inflammation" of the "Collagen", and go to "Edemize" "first" and then, in the Chronicization of the phenomenon, to "thicken" sclerosing the "Trabeculate of the Schlemm's Channel", (made of Collagen), making it narrower and reducing the room for the passage of the aqueous humor and also reducing consistently the normal drainage "flow rate" resulting in a progressive increase in the internal pressure of the eye: => **Glaucoma.**

The "Corneal Trabeculate", where the outflow of aqueous humor occurs: is the "drainage pipe" of the same "aqueous humor - draining' system", made, as already explained above, by Collagen as well as the: "Lamina Cribrosa Sclerale", network, through which pass the "myelinated fibers" of the Optic Nerve and the "Blood and Lymphatic Vessels", which, "progressively thickening", are "Strangling and Ischemizing" them. Chronic Glaucoma" can therefore be classified as:

-Collagenopathy by->Inflammatory-Chronic-Sclerosing-Disease-

Treatment, in a modern "Holistic Vision" cannot, therefore, be only of the "Organ", as up to now happened with Allopathic Therapies, but rather of "System":

the whole "Collagen network system" both of the "Trabeculate in Schlemm's Canal" (where the initial outflow of aqueous mood occurs) and of the "Lamina cribrosa" (where the myelinated neuritic terminations fibers, Vessels and Lymphatics of the Optic Nerve pass through)

Materials and methods:

"General administration of "Homotoxicological and organotherapeutic anti-inflammatory drugs", for specific draining, detoxifying and stimulating "Cellular / Tissue Collagen-Regeneration".

The "local" administration of "Galenic Eye Drops", "conceived and successfully tested", with a "Cocktail of Homotoxicological drugs" which leads to a "slow but gradual improvement" of the "Endo-ocular Pressure" within 3-6 months by administering it 6 -10 times a day: during the day, before falling asleep, as you get up during the night and in the morning as soon as you wake up. This local administration will lead, in its process of "progressive detoxification" and consequent "dis-inflammation", to a slow and progressive reduction up to the complete "normalization" of the thickness of the "webs" of the "Ocular Drainage Collagen System" reactivating a "regular outflow"

and the maintenance of a "normal" or slightly "hypotonic" "Endo-Ocular Pressure" thus favoring a greater "Hematic-Turn-Over" with a "greater venous return", improving "Oxygenation" of the Retina, blood and lymphatic vessels and of the myelinated neuritic fibers of the Optic Nerve.

Personal Note:

// This discovery is based on an "Intuition", inspired by the Most High, in a moment of profound consternation at the evidence of my progressive and unstoppable Visual deterioration, including the "Pharmacological Tachyphylaxis", which, after 40 years of Chronic Glaucoma, led me to ask Him for help.

The help was immediate, with the "intuition" and the immediate "consideration" that according to traditional: "Chinese Natural Medicine" there is a "Twinning between hollow (or empty) organs and full organs", therefore, "Eye" which is a "Full Organ" is "Twinned", by the meridian' connections of "Chinese Natural Medicine", with the "Stomach" which is a "Hollow Organ".

I understood in a moment that the Solution was to "Reverse the Paradigm" and treat "the Eye" as if I had to treat the "Inflamed Stomach", and therefore I understood how the Origin and Cause of Chronic Glaucoma was the consequence of an: Intoxication ->Chronic-Inflammation->Sclerosis //

*You will realize at some point, after a few months of Therapy, that no longer should be needed all those daily administrations and that their number could be, "progressively", decreased, always keeping the Ocular Pressure "under control", as the "detoxification", that it is the "Reset", proceeds and the Chronic Inflammation decreases, "the organism slowly regains" its "balance" and the Eye the "normalization" of the "pressure" and an "effective complete oxygenation".

3) It must be pointed out that if the Patient - does not - "definitely change" many of his "Wrong eating habits and lifestyle" with the "administration only" of one : =>

"Correct detoxification and normalization therapy of Chronic Inflammation" and therefore of the consequent reduction and possible arrest of the "Storm-Cytokines", it will not be "sufficient" to "normalize" the "Ethio-Pathogenetic Framework" in a "definitive way".

The persistence of "Pathogenic Noxa" does not allow for a "Real and Deep Detoxification" and therefore a true and lasting "Normalization of functions and systems" that means "Healing".

Fortunately, even with an "incomplete" "Restitutio ad Integrum"=" Return to Integrity", which will

not be able to reach a "Complete Biological Normalization", the "Stem Cells" will be "usefully" reactivated, because "wisely programmed" to be able to function even in the presence of "limited imperfections" of "Biological-Functional-Systems" to stop the disease that had "become chronic".

Therefore, if the Patient does not change "radically" his "Lifestyle" by correcting "many" of his "Wrong Nutritional Habits", only transitory improvements can be achieved, even if with a good improvement in the "Intraocular pressure" and "Sight", but he "Never" could reach one:

"Real Complete Healing" #.

We must make sacrifices to defeat our Worst Enemy: The "Habits"

#We should also "know" how to eat "without harming ourselves", that is not an easy task, nor, can be explained in this work, we live in a "Fake World and eat Fake Food" that it is sure for every "affected" patient, and we have also many wrong Life-Styles that affect our lives too#

Disease' Behaviour:

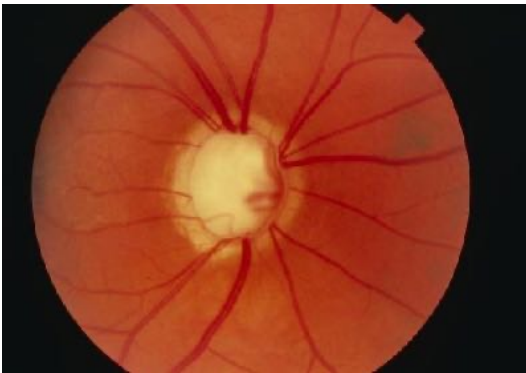
Is useful to remind that many Chronic Glaucoma suffer "most severe damage during the night":

- 1) Not being conscious, while sleeping, one usually does not notice the more or less slight soreness of the eyeballs due to the increased "Endo-Ocular" pressure, also because over time the "neurosensory pressure' terminals" "get used to the pain", depriving the patient of the most important "Alarm' Bell" to realize the "progressive worsening damage".
- 2) Because, often, we go to sleep after more or less abundant and / or toxic "Libations", and often, soon after dinner, we have not given the stomach the right time to digest "sufficiently" and therefore "Increasing the Toxic-Inflammatory Load" and with the release of the "toxins" a new "Cytokine Storm" develops and a new worsening due to the further "Thickening" and "Reactive-Inflammatory-Sclerosis" and then "Ischemizing" further the "Trabeculate of Schlemm's Canal" and the "Collagen network "Of the" Cribrosa Scleral Lamina "of the Optic Nerve through which the nerve fibers and vessels pass "Progressively Strangling and suffocating them" for an "Ischemic Anoxia" with the "progressive narrowing, from reactive thickening", of the Scleral "Lamina Cribrosa" of the Optic Nerve.

/ In fact, even after having achieved the normalization with a successful Antiglaucomatous Surgery, and additionally a "Hypotension", of the Endo-Ocular Pressure, since "field and visual

damage do not cease" indeed at contrary "continue to worsen" as, or, more slowly than before, "demonstrating" that in the Pathology is not "only" the "pressure increase of the Eye" that is the "Cause" of the progressive damage of the Nervous fibers, but, that there is also an "other Cause" equally and perhaps "more compromising" that causes a more definitive Damage to the Retina and the entire Optic Nerve./

3) The increased Ocular Pressure directly causes the "crushing of the photoreceptors" and the "neuritic fibers of the Optic Nerve Kneeling on the Retina' Optic Nerve Head" and then "strangling and ischemizing" them, "compressed" against the "rigid circular ridge" that is the "scleral' hole circle" where Optic Nerve fibers and Vessels pass through, opening like an "umbrella "into the Retina.



4) Photo of the Retina with the Head of the Optic Nerve like a "Funnel" Excavation and Optic Nerve Bleaching for Ischemia of Retinal Vessels that "Kneel" due to excessive Endo-Ocular Pressure on the compact circular ridge of the "Scleral Hole" where the "un-myelinated" neuritic fibers and vessels of the Optic Nerve pass through.

With the progressive damage of the sight, field of vision and colors up to their loss.

While there is, at the same time, a progressive shrinkage, a "Strangulation" of all the "Collagen Networks" with the "Progressive-Toxic-Inflammatory-Ischemic-Process" consequent to an "Edema" first and a "Sclerosis" after, with a progressive "Thickening" of the "Scleral Cribrosa' Lamina"= "Cribrous Foil" of the Optic Nerve which "progressively strangles" the "myelinated neuritic fibers" and the blood and lymphatic vessels of the Optic Nerve.

This explains, "conclusively", how and why the definitive damage to the neuritic fibers of the Optic Nerve can progress even after the primary "pressure problem" has been, "optimally", already resolved (with an intervention), with the "normalization" or even the "hypotension" of the Endo-Ocular Pressure.

Clinical cases, solved:

First case is the **Author**, who was able to live and see the darkness slowly but surely fall upon his

eyes, before having found the "correct path to follow", and after having finally understood the "Causes of the Disease" and "How to cure", who began to see the light and the contrast of the images improve, day after day, and the colors resume in a slow but progressive way as well as the "vision" and "Visual Field" while "normalizing" also the Endo-Ocular Pressure.

The feeling of recovery and the awareness that the problem may have been solved is contemporary with the progress of the effectiveness of Local and General Therapy and can only be understood by having experienced it in person, as happened to me, and this for the Will of the Most High.

After the first improvement and the conscious progression of my Healing, I began to treat my patients with "identical Treatment" and "identical results", "all them improved" already with the local treatment with the "Galenic eye' drops" I designed and prepared and have been (cured and) healed all those who have had the "courage and constancy to change" their "wrong lifestyle" and "nutritional habits" forever, after a profound process of Detoxification and Drainage "inducing" a "Regeneration-of-Retinal-and-Optic-Nerve-Stem-Cells".

Conclusions:

The therapy I experienced, while it generates a progressive reduction of the reactive inflammatory thickening of Collagen structures, oxygenating the same structures and Retinal Photoreceptors, unmyelinated neuritic fibers (first in the intra-ocular tract and then in the tract that crosses the "Lamina Cribrosa "and out of the eye into the optic nerve) and finally all the retinal and lymphatic vessels" promoting "a:

"Self-healing" from "Biological Reset"

obtained by "spontaneous reactivation" of "Autologous Stem Cells" which finally, with the substantial reduction of circulating inflammatory toxins that had induced an "abnormal" Cytokines "activation", they can resume their "natural and spontaneous ability to repair biological damage" of any kind, since they had been "deactivated" by the absence of a sufficient "biological balance" for the "Chronic-Reactivity-to-Cytokines-Waterfall" that causes a "block" or "strongly reduces" the "Activity and Spontaneous Regeneration of the Stem Cells themselves" which "have been "designed" to undergo "acute or short" but "not persistent" inflammatory processes, therefore the activation and the "persistence of Cytokines "inhibits" the "automatic reparative response" of the

same Stem Cells that "no longer recognize" the "original biological program", with which they had been created and programmed, "confused, inhibited and disoriented" by the Chronicization of the "Cytokine Storm".

Final summary:

My Therapy "Reset first and then reprogram" the Autologous Stem Cells, having "substantially reduced the excess of circulating cytokines" which prevented their spontaneous "Re-activation".

Please Note: By "Reprogramming" of Stem Cells I mean the possibility of bringing the same Stem Cells as close as possible to the "Original Programming of the "man / woman' Cyborg"

(which is formed by a Softer and a Hardware as a "very advanced Biological Computer") performed with the "Initial Environmental Biological Programming' conditions" when happened: the "Act of the Creation of Man and Woman" in the Eden.

So with the understanding of the "principles of correct biological functioning" we can: "Correctly cure and often Heal" diseases.

Much of what I discovered is also thanks to the "Teaching" of my "Grand-Masters" whom God in his Great Generosity made me meet to make me walk the path He designed for me.

The Late:

Prof. Aldo Spirito, Biologist University' Lecturer in Rome, proposed for the Nobel Prize in Science.

Prof. Giovanni Battista Bietti, President of the O.M.S. for Ophthalmology, Professor in Rome.

Prof. Svyatoslav Nicolajevich Fyodorov, Academyc of Sciences of Russia, Director of the "Moscow' Eye Micro-Surgery Center".

Prof. Orfilio Pelaez, Director of the Center for the Treatment of "Retinitis Pigmentosa" : "Camillo Cienfuegos" Havana, Cuba, "creator" of the "Eye Revascularization", in fact, He has been the "unconscious precursor" of the "Regeneration of Ocular Stem Cells".

And a 5th "Grand Master": Prof. Leonello Milani, President of the "International Academy of Physiological Regulatory Medicine" that with its "Master's Lessons" made me grow in Scientific Knowledge, allowing me to reach my latest discoveries in Homotoxicology.

Below is a List of Discoveries and Inventions, of the Author, in the "Medical Field", to make better understand that "nothing happens by chance" and that the true scientist is a "researcher" aimed to understand, with "Net Mind and Spirit", the "Principles", first and then the "Mechanisms", of Nature, often helped, in various ways, from the Most High.

1) The Correction of "High Myopias" with a "Diamond Micro-Scalpel" (free hand) : with the R.K. (Radial Keratotomy) = "Radial Keratotomy" which, with a program "devised" by me, allowed to correct up to - 21 diopters, having passed all the programs of a "Data and Program Computerized Processing Center in Prof.Fyodorov'Institute", in Moscow, with "ruler, pencil and graph-paper", 1982.

2) "Cryogenic Treatment" on the Cornea with the "Cryo" (cryogenic probe for the "intracapsular extraction of the Cataract" which cools down to - 70 degrees cent.) in Herpes Simplex "relapsing keratitis", with their definitive "Healing", 1982.

3) the "Immuno-modulating Medical Therapy" which stops the Progressive Myopia caused by a group of "Neuro-Angiotropic Viruses" which prevent, "delaying" it, to terminate the "genetic program" of "elongation of the Eyeball" from the "intrauterine waist" to the "normal length of 22.5 mm (front-back measurement of the Eye-bulb) of the Adult "with a 3/6 months" Medical Therapy, 1982.

4) first "closed" cataract surgery, in elevated myopic, "Without Incision and Suture" with 2 separated entrances for the needles : one "aspirating needle", (including the "safe" cleaning of the capsule), split from a second one for the "infusion" each one of 1 mm in diameter, 1983.

5) Realization of a "coaxial-needle" for Cataract Operation, of 1.2 mm in diameter, 1 "aspirating", with an automatic valve, (designed by me), with a pre-calibrated silicone vent tube (in order not to exceed the breaking pressure limit of the capsule), and 1 coaxial to first "irrigating", mounted on a "disposable"(plastic) syringe, that did the same job as a "Kelman's Phaco computer-machine" (but cheaper: 1,000 lire against 70,000,000 lire) and without need of electricity, thus allowing "advanced intervention" even in primitive places, 1984.

6) the A.R.K. (Asymmetric Radial Keratotomy) technique used today by me as "Mini-A.R.K.", to obtain a "Corneal Geometrical Implosion" with first result to "Re-increase" central-paracentral "Corneal thickness", (thinned due to Keratoconus) and second the "simultaneous correction" of the "Secondary Refractive Defect" as Astigmatism and / or / Myopia or both, resulting from the

Keratoconus' Corneal Curvature Pejorative Modification, 1984.

7) the first surgery of "congenital cataract" in "extracapsular + IOL-Sputnik implant", with the needle, (which I invented), in an 8-month-old child in the Ophthalmology Department of the Colombo Hospital in Sri Lanka, 1985.

8) the discovery of "Aspergillosis" as the "true cause of Keratoconus" that it is, in fact, a "Corneal Collagen Infection" = "Collagenopathy Secondary to Fungal Infection" with strong weakening and destructuring of the "Collagen Fibrils" that with the application of the "Bio-Electronic-Resolutive-Therapy" reaching therefore the "Complete Resolution" of the Disease, (no more "stupid Theories" with the involvement of "genetic Diseases"), 1986.

9) LASIK (Femtosecond-Laser surgery), a Technique I conceived and tested (already on Pig's eyes) with the Prof. Draegger' Microkeratome in 1989.

10) First Autologous Stem Cell Transplants in the "Eduardus KrankenHaus" Hospital in Cologne, Germany, with the authorization and supervision of the German Ministry of Health, February 2008.

11) the subsequent discovery of "Regenerative Informational Medicine" of the Autologous Stem Cells, without the need for "direct transplantation" of same Stem Cells, end of 2008.

12) definition of "Biological Life and Biological Information" and of "True Nature of Water'Memory" a "debated topic" but "never discovered" even by Eminent Nobel Prizes (Benveniste, Pop, Mantagnier and others) with my "Discovery" of "Ice-Micro-Crystals " in blood and intra and extra-cellular body fluids, which "preserve the Memory of Biological Programs like a Micro-Chip" throughout the body, January 2009.

13) current discovery of the "Biological Reset with Healing of Chronic Glaucoma" with appropriate local and general therapy, January 2021.

Bibliography:

1) "Retinal Stem Cells Reprogramming" - Journal of Ophtalmology & Clinical Research, ISSN: 2573-9573 (8/1/2018). Dr. Massimo Lombardi

2) "Retinal Stem Cells Reprogramming Using Omotoxicological Pharmaceuticals Blend Therapy" through Retrobulbar Injections,-Journal of Stem Cell Research,(13/4/2018). Dr. Massimo Lombardi

3) "Retinal and Body 'Stem Cells Reprogramming" - Acta Scientific Ophtalmology ISSN: 2582-3191 (19/5/2021). Dr. Massimo Lombardi

4) "Keratoconus Etiopathogenesis and True Cure: Modern Concepts" - Journal of Clinical Review & Case Reports, ISSN: 2573-9565 (30/04/2018). Dr. Massimo Lombardi